

Peripheral MR Angiography with Blood Pool Contrast Agent: Prospective Intraindividual Comparative Study of High-Spatial-Resolution Steady-State MR Angiography versus Standard-Resolution First-Pass MR Angiography and DSA¹

Dariusch R. Hadizadeh, MD
Jürgen Gieseke, PhD
Stefan H. Lohmaier, MD
Kai Wilhelm, MD
Jack Boschewitz, MS
Frauke Verrel, MD
Hans H. Schild, MD
Winfried A. Willinek, MD

¹ From the Departments of Radiology (D.R.H., J.G., S.H.L., K.W., J.B., H.H.S., W.A.W.) and Vascular Surgery (F.V.), University of Bonn, Sigmund-Freud-Strasse 25, D-53105 Bonn, Germany; and Philips Medical Systems, Best, the Netherlands (J.G.). Received November 20, 2007; revision requested January 21, 2008; revision received March 6; accepted April 18; final version accepted May 21. **Address correspondence to** W.A.W. (e-mail: Winfried.Willinek@ukb.uni-bonn.de).

© RSNA, 2008

Purpose:

To prospectively compare the accuracy of high-spatial-resolution steady-state magnetic resonance (MR) angiography with standard-resolution first-pass MR angiography in the lower extremities, with digital subtraction angiography (DSA) as the reference standard.

Materials and Methods:

Institutional ethics committee approval and written informed consent were obtained. Twenty-seven patients (16 men, 11 women; mean age, 64.4 years \pm 14.8 [standard deviation]; range, 26–87 years) suspected of having or known to have peripheral arterial disease underwent first-pass and steady-state MR angiography and DSA. First-pass and steady-state MR angiography were performed in the same patient in the same session and with the same dose of blood pool contrast agent. The most severe stenosis grade of each evaluated segment was measured; sensitivity, specificity, and positive and negative predictive values were calculated at first-pass and steady-state MR angiography, with DSA as the reference standard. The κ coefficient was used to measure the agreement between first-pass MR angiography, steady-state MR angiography, and DSA.

Results:

A total of 334 arterial segments were available for intraindividual comparison of first-pass MR angiography, steady-state MR angiography, and DSA in 27 patients. In 20 (74%) of 27 patients, the stenosis grade of at least one of the evaluated vessels differed at steady-state MR angiography from that at first-pass MR angiography. In total, stenosis grade was judged as higher at first-pass MR angiography than at DSA (overestimation) in 28 of 334 segments and as lower (underestimation) in 15 of 334 segments. The stenosis grade as judged at steady-state MR angiography matched with that at DSA in 334 of 334 vessel segments.

Conclusion:

High-spatial-resolution steady-state MR angiography allowed for better agreement with DSA regarding stenosis grade in patients with arterial disease compared with standard-resolution arterial-phase first-pass MR angiography.

© RSNA, 2008

Supplemental material: <http://radiology.rsna.org/cgi/content/full/2492072033/DC1>

Three-dimensional (3D) contrast material-enhanced magnetic resonance (MR) angiography has become a routine application in the assessment of the vasculature in many regions of the body (1–3). In patients with peripheral arterial occlusive disease, 3D contrast-enhanced MR angiography is an alternative to digital subtraction angiography (DSA), which still is considered the standard of reference (4) and is performed as the initial imaging study in many centers.

Standard gadolinium chelate contrast agents do not remain in the vascular lumen but rapidly extravasate into the interstitial space, which reduces intravascular contrast and therefore limits the maximum acquisition time for arterial imaging to the arterial bolus passage (5). Therefore, 3D contrast-enhanced MR angiography has focused primarily on arterial imaging without venous enhancement, with a resultant inherent limitation in the maximum spatial resolution that can be obtained due to limited available acquisition time (6–10).

New contrast agents that result in prolonged vascular contrast, blood pool contrast agents, were evaluated for 3D contrast-enhanced MR angiography (11,12). However, these studies focused on the comparison of blood pool contrast agent-enhanced 3D MR angiography with nonenhanced time-of-flight MR angiography. As the first blood pool contrast agent, gadofosveset trisodium was approved for clinical application in the European Union. Gadofosve-

set trisodium reversibly binds to albumin, increasing T1 relaxivity ($r_1 = 19 \text{ L} \cdot \text{mmol}^{-1} \cdot \text{sec}^{-1} \pm 1$ [standard deviation] at 1.5 T and 37°C in plasma; standard gadolinium chelate contrast agent, $r_1 = 3.4\text{--}6.6 \text{ L} \cdot \text{mmol}^{-1} \cdot \text{sec}^{-1}$) and extending vascular contrast enhancement during an equilibrium phase (steady state) that lasts for at least 1 hour (13–15).

The extended available acquisition time with a blood pool contrast agent holds promise for acquisition of submillimetric 3D contrast-enhanced MR angiograms and therefore enhanced vascular delineation compared with that at standard-resolution 3D contrast-enhanced MR angiography. However, extended acquisition time during the steady state results in simultaneous enhancement of arteries and veins that may interfere with image interpretation. The purpose of this study was to prospectively compare the accuracy of high-spatial-resolution steady-state MR angiography with the blood pool contrast agent gadofosveset trisodium with standard-resolution first-pass MR angiography with the same blood pool contrast agent in the lower extremities, with DSA as the reference standard.

Materials and Methods

Only those authors who are not employees of Philips Medical Systems (Best, the Netherlands) had control of inclusion of any data and information that might present a conflict for the author (J.G.) who is an employee of this com-

pany. Prior to this study, Bayer Schering Pharma (Berlin, Germany) provided contrast medium for sequence optimization.

Patients

In a prospective, intraindividual comparison study, 27 consecutive patients (mean age, 64.4 years \pm 14.8; age range, 26–87 years) (16 men; mean age, 63.3 years \pm 16.1; age range, 26–87 years) (11 women; mean age, 66.0 years \pm 13.4; age range, 45–85 years) suspected of having or known to have peripheral arterial disease who were referred for 3D contrast-enhanced MR angiography and DSA at the Department of Radiology of the University of Bonn were examined between April and November 2006 by using first-pass MR angiography, steady-state MR angiography, and DSA. Before patients were enrolled in this study, the study protocol was approved by the institutional ethic committee, and written informed consent was obtained from all patients. Clinical indications included claudication in 11 cases (Fontaine stage IIb), critical limb ischemia in 13 cases (Fontaine stage III [$n = 4$] and IV [$n = 9$]), Wegener granulomatosis in one case, thromboangiitis obliterans in one case, and suspicion of peripheral embolus after interposition of iliac artery bypass graft in one case (16). Exclusion criteria were contraindications for 3D

Advance in Knowledge

- When compared with digital subtraction angiography (DSA), contrast-enhanced high-spatial-resolution steady-state MR angiography with a blood pool contrast agent resulted in increased sensitivity and specificity in the detection of significant stenosis of peripheral arteries of the lower extremities compared with those of standard-resolution first-pass MR angiography with a blood pool contrast agent.

Implication for Patient Care

- The higher agreement of contrast-enhanced high-spatial-resolution steady-state MR angiography with a blood pool contrast agent with DSA compared with that of standard-resolution first-pass MR angiography with a blood pool contrast agent in the detection of significant stenosis of peripheral arteries of the lower extremities may translate into improved selection of candidates for surgery or intervention.

Published online before print
10.1148/radiol.2492072033

Radiology 2008; 249:701–711

Abbreviations:

CI = confidence interval
DSA = digital subtraction angiography
3D = three-dimensional

Author contributions:

Guarantors of integrity of entire study, D.R.H., H.H.S., W.A.W.; study concepts/study design or data acquisition or data analysis/interpretation, all authors; manuscript drafting or manuscript revision for important intellectual content, all authors; manuscript final version approval, all authors; literature research, D.R.H., J.B., H.H.S., W.A.W.; clinical studies, all authors; statistical analysis, D.R.H., W.A.W.; and manuscript editing, all authors

See Materials and Methods for pertinent disclosures.

contrast-enhanced MR angiography (eg, pacemaker, allergy).

Although attempts were made to randomize the order of 3D contrast-enhanced MR angiographic and DSA examinations, 3D contrast-enhanced MR angiography was performed first in the majority of patients (19 of 27) because of at least one of the following clinical requirements: pending laboratory test results necessary to perform the DSA procedure, planning of the localization of the intraarterial access for unilateral DSA, and/or availability of the imaging modality due to emergency procedures. Clinical treatment was not delayed for any patients because of study participation. The mean time between DSA and 3D contrast-enhanced MR angiographic examinations was 19.3 days ± 24.4 (range, 1–107 days).

In eight patients, unilateral DSA was available for comparison with 3D contrast-enhanced MR angiographic results; this was because of former amputation of the other extremity in two patients and the need for one-sided DSA after antegrade puncture in preparation for an interventional procedure in the other six patients. In one other case, a femoropopliteal bypass was performed after DSA and before 3D contrast-enhanced MR angiography. In this patient, the upper leg segments were excluded from the study. Figure 1 illustrates the study design. All patients were asked to report any adverse events and overall toleration of the procedure.

MR Imaging

Three-dimensional contrast-enhanced MR angiography was performed with a 1.5-T whole-body imager (Achieva; Philips Medical Systems) (maximum gradient amplitude, 33 mT/m; slew rate, 200 T/m/sec). A commercially available flexible four-channel phased-array coil (Philips Medical Systems) was used for imaging the lower legs. Images of the upper legs and pelvic region were acquired with an integrated body coil. A biphasic injection protocol was implemented with automatic power injection (Spectris; Medrad Europe, Beek, the Netherlands) of contrast medium.

Gadofosveset trisodium (Vasovist; Bayer Schering Pharma) was injected at a flow rate of 1.2 mL/sec followed by a 25-mL saline flush at a flow rate of 0.6 mL/sec. First-pass MR angiography was initiated when the contrast medium reached the common iliac arteries as determined by using fluoroscopic triggering (17).

Acquisition parameters for the coronal T1-weighted gradient-echo sequences during first-pass MR angiography and steady-state MR angiography are shown in Table 1. The sequence flow is illustrated in Figure 2.

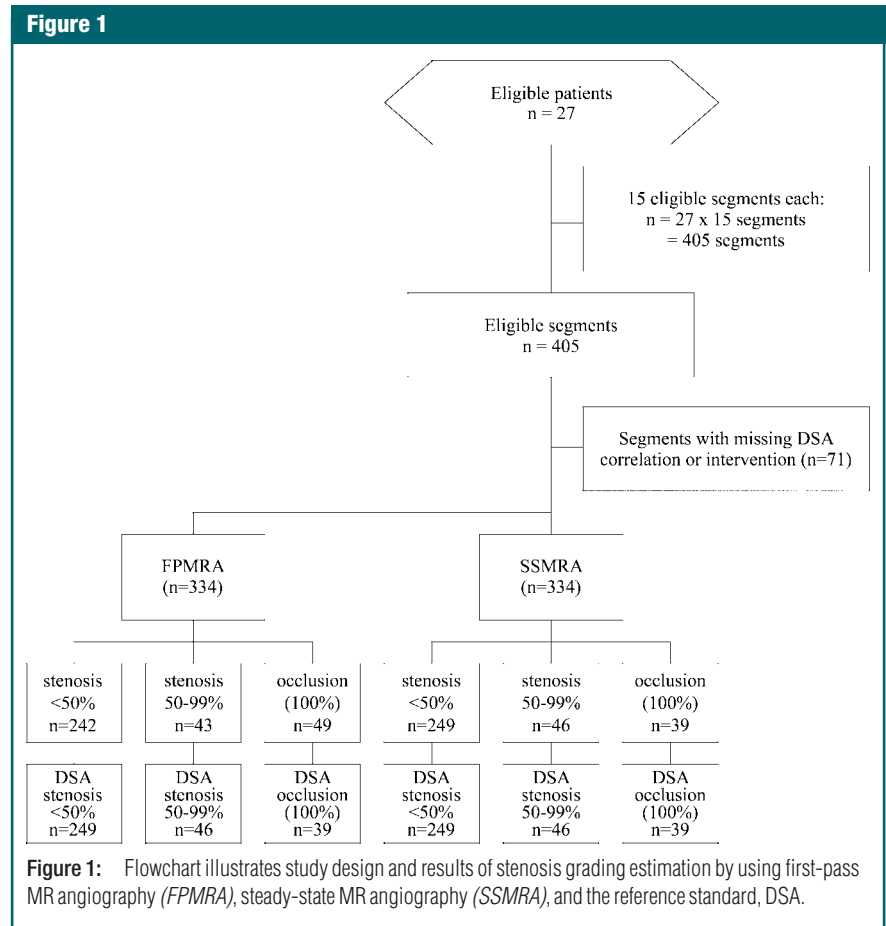
Steady-state MR angiography was started in the same session as first-pass MR angiography with the same contrast medium after a delay of 4 minutes (18,19). First-pass MR angiographic native masks were electronically subtracted from contrast-enhanced first-pass MR angiographic acquisitions for

reconstruction of maximum intensity projections.

Conventional Angiography

DSA is widely accepted as the standard-of-reference procedure for the estimation of the grade of stenosis of diseased vessel segments in peripheral arterial occlusive disease (20). DSA was performed by using a flat-panel C-arc angiographic unit (Allura Xper FD20; Philips Medical Systems). System detector size was 48 cm, field of view could be chosen from 15 to 48 cm, pixel size was 154 × 154 μm, and matrix was 2048 × 2048.

A 5-F introducer sheath was placed in the common femoral artery, and a 5-F pigtail catheter was placed in the suprarenal abdominal aorta to obtain DSA series of pelvic and leg arteries. After the aortic bifurcation was located, the catheter was replaced to a position



cephalad of the aortic bifurcation. Each series was obtained after administration of 20–35 mL of contrast medium at 10–12 mL/sec (iopamidol, Solustrast 300, 300 milligrams of iodine per milliliter; Altana Pharma, Konstanz, Germany). A total of 150–190 mL of contrast medium was given for each examination, which consisted of six to eight series. In terms of single-sided angiography, an 18-gauge needle (or if before intervention, a 6-F introducer sheath) was placed antegrade in the common femoral artery. Four to five runs were achieved after manual delivery of 6–15 mL of contrast medium per run, leading to a total of 42–65 mL of contrast medium.

Blood Pool Contrast Agent

Gadofosveset trisodium (Vasovist; Bayer Schering Pharma) is a gadolinium-based contrast agent with prolonged plasma half-life and increased relaxivity ($r_1 = 19 \text{ L} \cdot \text{mmol}^{-1} \cdot \text{sec}^{-1} \pm 1$ at 1.5 T and 37°C in plasma) because of an additional diphenylcyclohexyl group that reversibly binds to plasma albumin (21). Gadofosveset trisodium was applied at the recommended dosage of 0.03 mmol per kilogram of body weight in all patients (22). The average total applied dose was $9.1 \text{ mL} \pm 1.7$ (range, 6–14 mL).

Image Analysis

The maximum grade of stenosis (most severe stenosis) of each arterial vessel segment of the lower extremities was evaluated in consensus by two radiologists (D.R.H., 5 years of experience in vascular radiology; W.A.W., 8 years of experience in vascular radiology) on first-pass and steady-state MR angiograms. The interpretation was performed at two separate reading sessions 4 weeks apart. The readers were blinded to the patients' names, clinical histories, and to the results of other diagnostic procedures, including DSA. Cases were reviewed in randomized order on a postprocessing workstation (Viewforum; Philips Medical Systems). The readers used interactive reformation at the time of interpretation, including maximum intensity projections and multiplanar reformations.

The following segments were evaluated: aorta, iliac outflow (common iliac artery, external iliac artery, and common femoral artery), superficial femoral artery, popliteal artery, anterior tibial artery, tibial peroneal trunk, peroneal artery, and posterior tibial artery.

Maximum stenosis grade was measured as follows: The area of enhancing vessel lumen in a stenosed segment in a plane perpendicular to the track of the vessel (SL) was measured, as well as the

area of the enhancing vessel lumen of the same vessel in a distal nonstenosed segment (NL) on first-pass and steady-state MR angiograms (23–25). The grade of vessel stenosis was calculated as follows: $(\text{NL} - \text{SL})/\text{NL}$. Cross-sectional stenosis measurement obtained in this manner has previously been shown to be a more accurate stenosis grading than with in-plane views (24,26,27). Readers were asked to indicate whether or not venous enhancement interfered with image interpretation of arterial stenosis grading on steady-state MR angiograms. In addition, for visualization of stenosis grade, manual curved multiplanar reformations of the vessel of interest were reconstructed by following the centerline of the vessel (28). The results of these measurements were evaluated according to the following scaling scheme: no significant stenosis (<50%), high-grade stenosis ($\geq 50\%$ –99%), or occlusion (100%). A threshold of stenosis grade of 50% has previously been used as a primary efficacy variable in major trials for the detection of clinically relevant stenosis in peripheral arterial occlusive disease (11–13,29,30). In all cases, a consensus opinion was reached without a discrepancy between the two readers with regard to grade of stenosis.

In a second step, the grade of steno-

Table 1

Technical Parameters of T1-weighted Gradient-Echo Sequences for First-Pass and Steady-State MR Angiography

Parameter	First-Pass MR Angiography			Steady-State MR Angiography		
	Pelvis	Upper Legs	Lower Legs	Pelvis	Upper Legs	Lower Legs
Repetition time msec/echo time msec	2.7/0.89	2.8/0.94	4.8/1.36	4.8/1.42	4.9/1.44	5.8/1.68
Flip angle (degrees)	25	25	25	25	25	25
Field of view (mm)	451	451	451	451	451	451
Rectangular field of view (%)	100	100	100	100	100	100
Slab thickness (mm)	104	90	88	135	94.05	83.3
Image matrix	384 × 285	336 × 252	400 × 300	400 × 300	416 × 312	464 × 348
Partition	65	60	80	90	95	170
k-Space acquisition order*	CENTRA	CENTRA	CENTRA	Linear	Linear	Linear
Acquired voxel (mm)	1.48 × 2.33 × 1.60	1.34 × 2.11 × 1.50	1.13 × 1.77 × 1.10	1.13 × 1.48 × 1.50	1.08 × 1.42 × 0.99	0.97 × 0.97 × 0.49
Reconstructed voxel (mm)	1.04 × 1.04 × 1.60	0.88 × 0.88 × 1.50	0.88 × 0.88 × 1.10	0.88 × 0.88 × 1.50	0.88 × 0.88 × 0.99	0.52 × 0.52 × 0.49
Acquisition time (sec)	12.6	13.4	35.9	100	110	174

* CENTRA = randomly segmented central k-space ordering.

sis was evaluated by using DSA by one radiologist (K.W., 15 years of experience) who was not involved in the reading of 3D contrast-enhanced MR angiograms. The grade of stenosis of each vessel segment was evaluated by using the same scaling scheme for first-pass MR angiography, steady-state MR angiography, and DSA. To make sure that the same stenosis was taken for intermodality comparison, a fourth reader (J.B., 3 years of experience) compared the exact anatomic location of each stenosed vessel segment in patients with multiple stenosed vessel segments.

Statistical Analysis

For first-pass MR angiography, steady-state MR angiography, and DSA, 2×2 contingency tables were plotted. Thresholds were set for determination of insignificant (<50%) versus significant ($\geq 50\%$) stenosis and of patency (<100%) versus occlusion (100%). The κ coefficient was used to measure agreement between first-pass MR angiography, steady-state MR angiography, and DSA. To account for the dependency of different measurements in the same patient, we first calculated κ per patient and then calculated an overall κ (31). Sensitivity, specificity, and negative and positive predictive values, as well as their confidence limits, were calculated, with adjustment for the correlation between different measurements in the same patient by using generalized estimation equations. The estimated correlations were low (range, -0.020 to 0.062). All statistical analyses were performed with software (SPSS, version 14.0; SPSS, Chicago, Ill).

Results

First-pass and steady-state MR angiography were successfully performed in 27 of 27 patients. All patients tolerated the procedure well, and there were no adverse events. After exclusion of segments without DSA comparison, a total of 334 segments were available for intraindividual comparisons. All segments were satisfactorily visualized at first-pass and steady-state MR angiography. Both readers of steady-state MR angio-

grams independently indicated that the presence of veins on steady-state MR angiograms did not impair image interpretation in any of the 334 segments.

The grade of stenosis was judged as higher at first-pass MR angiography than at DSA in 28 (8.4%) of 334 segments (overestimation) (Fig 3 and 4; Fig E1, <http://radiology.rsnajnl.org/cgi/content/full/2492072033/DC3>) and lower at first-pass MR angiography than at DSA in 15 (4.5%) of 334 segments (underestimation) (Fig 3, 4, 5; Table 2). Of the 10 segments that were considered to be occluded at first-pass MR angiography but not at DSA, six were judged as high-grade stenosis ($\geq 50\%$) at DSA and four as no relevant stenosis (<50%) at DSA. The grade of stenosis as judged with steady-state MR angiography matched the grade of stenosis with DSA in 334 (100%) of 334 segments. The grade of stenosis as judged with first-pass MR angiographic readings matched the stenosis grading with DSA in 291 (87.1%) of 334 segments.

In 39 (11.7%) of 334 segments, the stenosis grading at DSA differed from that at first-pass MR angiography by one grade; in four (1.2%) of 334 segments, the grading differed by two grades (occlusion vs nonstenosed segment) (Table E1, <http://radiology.rsnajnl.org/cgi/content/full/2492072033/DC1>). Twenty-six (61%) of 43 segments with different grading at first-pass MR angiography and at DSA were located in lower leg segments, 14 (33%) of 43 segments were located in the upper leg segments, and three (7%) of 43 were located in the pelvis. In total, in 20 (74%) of 27 patients, the grade of stenosis of at least one of the patients' evaluated vessel segments was judged differently at first-pass MR angiography than at DSA.

Tables 3 and 4 display the decision matrices (2×2 contingency tables) for the comparison of the different modalities (first-pass MR angiography, steady-state MR angiography, and DSA) according to the thresholds of insignificant (<50%) versus significant ($\geq 50\%$) stenosis and patency (<100%) versus occlusion (100%).

For reporting of significant versus insignificant lesions, first-pass MR an-

Figure 2

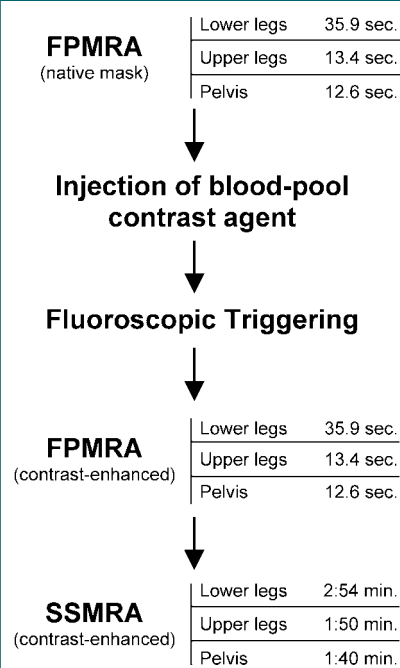


Figure 2: Diagram illustrates sequence flow of the combined first-pass (FPMRA) and steady-state MR angiographic (SSMRA) protocol used in this study.

giographic results showed a sensitivity of 82.1% (95% confidence interval [CI]: 72.9%, 88.7%), specificity of 91.0% (95% CI: 86.4%, 94.2%), positive predictive value of 75.4% (95% CI: 64.0%, 84.1%), and negative predictive value of 93.5% (95% CI: 88.3%, 96.5%). For the comparison of patent versus occluded segments at first-pass MR angiography, sensitivity of 100% (95% CI: 100%, 100%), specificity of 96.6% (95% CI: 93.3%, 98.3%), positive predictive value of 79.6% (95% CI: 66.6%, 88.5%), and negative predictive value of 100% (95% CI: 100%, 100%) were calculated. Because steady-state MR angiography and DSA stenosis grading matched in 334 (100%) of 334 segments, sensitivity, specificity, and positive and negative predictive values were 100% (95% CI: 100%, 100%) for both thresholds when these modalities were compared.

The overall κ coefficients that were

used to measure the agreement between first-pass MR angiography, steady-state MR angiography, and DSA revealed an overall κ coefficient for the agreement of first-pass MR angiography and DSA of 67.6% (95% CI: 60.0%, 75.3%) and an overall κ coefficient for the agreement of steady-state MR

angiography and DSA of 100% (95% CI: 100%, 100%).

Discussion

First-pass MR angiography of the arteries of the lower extremities at standard

spatial resolution with gadolinium-based contrast agents is highly accurate in the assessment of stenosis grading compared with DSA (1,20) and has been proposed as the first-line diagnostic tool in arterial vessel imaging (32). Likewise, the intravascular contrast

Figure 3

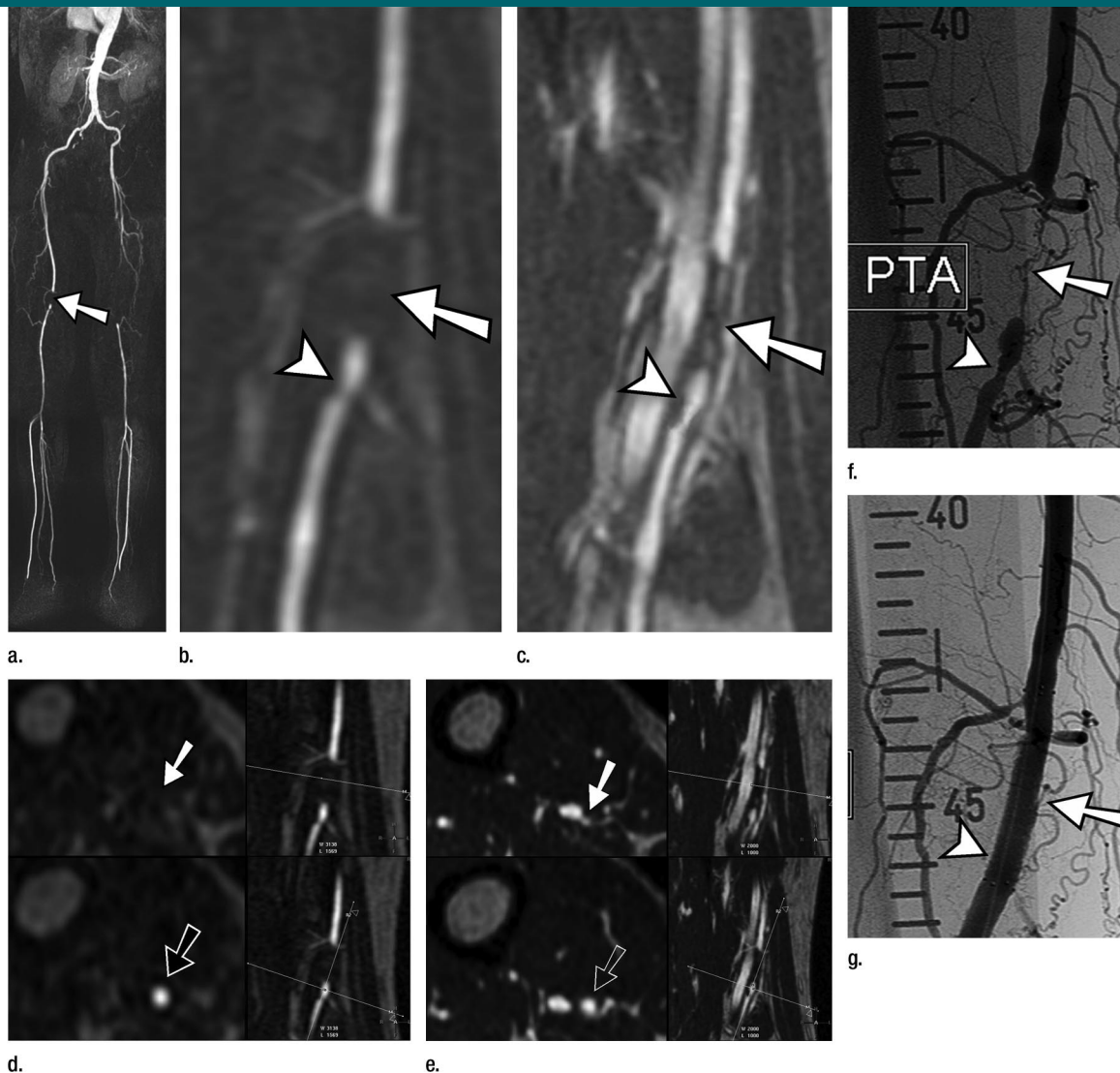


Figure 3: MR angiographic and DSA images of filiform stenosis of the right distal superficial femoral artery (solid arrow), 50% tandem stenosis of the same segment (arrowhead), and nonstenosed reference segments (open arrow) in a 65-year-old man. This patient was diagnosed with occlusion of the left superficial femoral artery, with reconstitution of the left popliteal artery. **(a)** Fused maximum intensity projection of moving-table-subtracted contrast-enhanced T1-weighted gradient-echo images. **(b)** Curved multiplanar reformation of contrast-enhanced T1-weighted gradient-echo images (2.8/0.94) during the arterial first pass. **(c)** Curved multiplanar reformation of high-spatial-resolution contrast-enhanced T1-weighted gradient-echo images (4.9/1.44) during the steady state (Movie, <http://radiology.rsna.org/cgi/content/full/2492072033/DC2>). **(d)** Cross-sectional multiplanar reformations of the same sequence as in **(b)**. **(e)** Cross-sectional multiplanar reformations of the same sequence as in **(c)**. **(f)** Anterior view of selective DSA of the right superficial femoral artery before percutaneous transluminal angioplasty (PTA) and **(g)** after intervention. Note visible residual lumen in **(c)** and **(e)** at the level of high-grade stenosis.

Figure 4

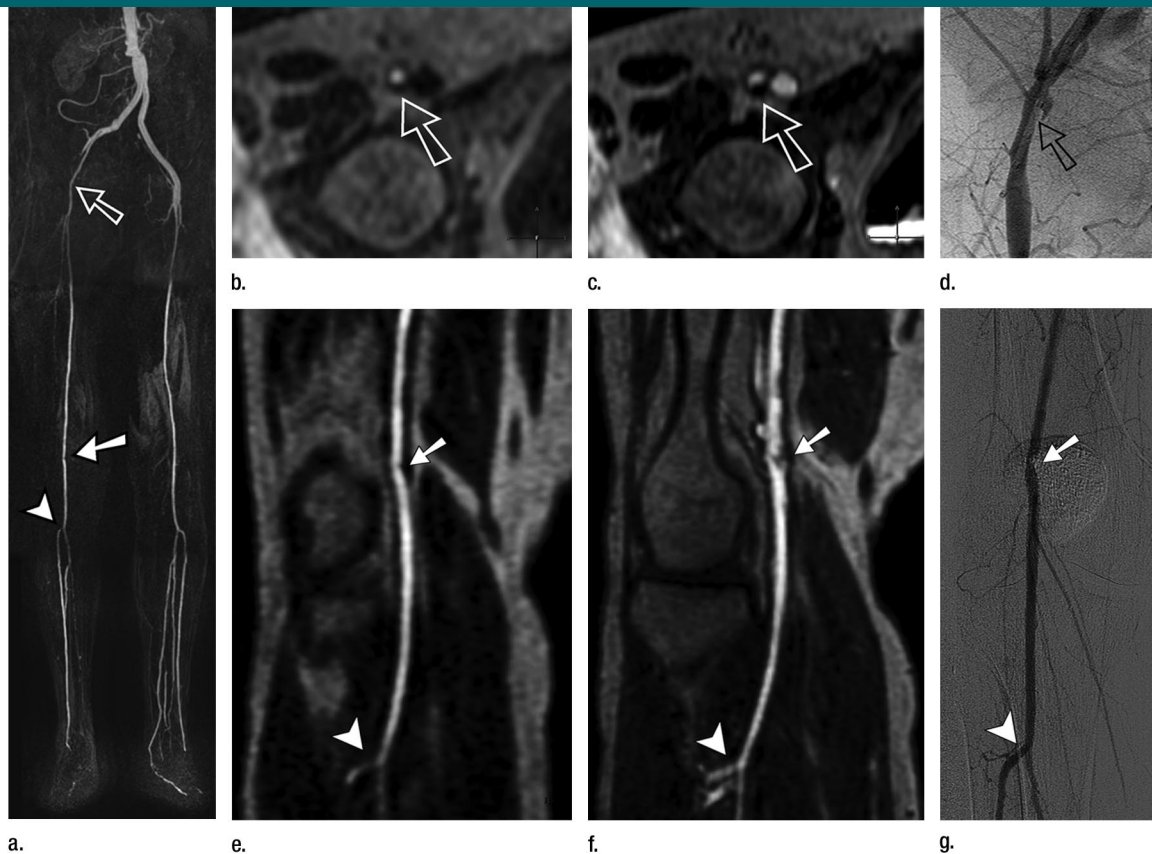


Figure 4: MR angiographic and DSA images of stenosis ($>50\%$) of the right common femoral artery (open arrow), high-grade stenosis of the right popliteal artery (solid arrow), and absence of stenosis at the origin of the right tibial artery (arrowhead) in a 56-year-old woman. This patient had a right aortoiliac and left aortofemoral bypass graft from previous surgery. **(a)** Fused maximum intensity projection of moving-table-subtracted contrast-enhanced T1-weighted gradient-echo images. **(b)** Cross-sectional multiplanar reformation of contrast-enhanced T1-weighted gradient-echo images (2.7/0.89) during the arterial first pass. **(c)** Cross-sectional multiplanar reformation of high-spatial-resolution contrast-enhanced T1-weighted gradient-echo images (4.8/1.42) during the steady state. **(d)** Anterior view of selective DSA of right common femoral artery. **(e)** Curved multiplanar reformation of contrast-enhanced T1-weighted gradient-echo images (2.8/0.94) during the arterial first pass. **(f)** Curved multiplanar reformation of high-spatial-resolution contrast-enhanced T1-weighted gradient-echo images (4.9/1.44) during the steady state. **(g)** Anterior view of selective DSA of right popliteal artery and proximal anterior tibial artery. Stenosis grade of right common femoral artery was judged as less than 50% on first-pass MR angiograms, but as 50% or higher on steady-state MR angiograms and DSA images (open arrow). Stenosis grade of right popliteal artery was judged as less than 50% on first-pass MR angiograms, but as 50% or higher on steady-state MR angiograms and DSA images (solid arrow). Note the better visualization of proximal right anterior tibial artery on steady-state MR angiograms than on DSA images (arrowhead). Stenosis grading of the latter segment was judged as 50% or higher on first-pass MR angiograms and less than 50% on steady-state MR angiograms and DSA images.

agent gadofosveset trisodium has been shown to allow for safe and effective MR angiographic studies during arterial bolus passage (11,12) and to have at least as good of image quality as standard extracellular contrast agents at 3D contrast-enhanced MR angiography (33). In addition to first-pass MR angiography, the application of gadofosveset trisodium allows for contrast enhancement

during steady-state MR angiography with minimal decline in signal- and contrast-to-noise ratios, which allows for the application of longer 3D contrast-enhanced MR angiographic sequences and thus the acquisition of higher resolution 3D contrast-enhanced MR angiograms of the vasculature (14). The accuracy of stenosis grading from this steady state has been shown in prelim-

inary studies (22,34). The ability to acquire steady-state MR angiograms of the lower extremities may markedly increase spatial resolution and diagnostic accuracy of MR angiography, but this has not yet been systematically examined.

Because of simultaneous enhancement of arteries and veins, which is inherent to steady-state MR angiography,

maximum intensity projections are not adequate for image evaluation with steady-state MR angiography because of venous overlay. In multiplanar reformations, however, steady-state MR angiography at a resolution of $0.5 \times 0.5 \times 0.5$ mm allows for the clear depiction of both arteries and veins without overlay, which allows for adequate stenosis grading of the enhanced artery despite simultaneously enhanced concomitant veins (35).

The acquisition of high-spatial-resolution steady-state MR angiographic studies is particularly useful in the evaluation of the grade of stenosis in the arteries of the lower legs and ankles. Patency of four segments at distant vessel levels of the peroneal artery was not demonstrated at first-pass MR angiography, whereas steady-state MR angiographic results revealed patency,

with stenoses judged as less than 50%. In all four cases, DSA helped confirm the diagnosis obtained at steady-state MR angiography. First-pass MR angiography alone is often nondiagnostic in this region of the body because of early venous enhancement in patients with pedal ulcers or in a postsurgical state and because of the inability to differentiate arteries from veins with a resolution of 1 mm^3 that is typically acquired at standard-resolution first-pass MR angiography with gadolinium chelate contrast agent. One alternative to overcome this limitation is the acquisition of time-resolved MR angiographic studies of the lower legs (eg, time-resolved imaging of contrast kinetics, or TRICKS) in a hybrid approach with two separate injections (36). This requires a high volume of contrast medium, which may be problematic, particularly for patients

with impaired renal function who are at risk for nephrogenic systemic fibrosis. Even though no cases of nephrogenic systemic fibrosis have been reported after administration of gadofosveset trisodium so far, the total number of its applications worldwide is still small compared with traditional gadolinium chelate contrast agents, including gadopentetate dimeglumine (Magnevist; Bayer Schering Pharma) and gadodiamide (GE Healthcare, Princeton, NJ), and its potential risk for nephrogenic systemic fibrosis will need further investigation.

Additionally, even with the newest imager technology, with a hybrid approach, there is still a trade-off between temporal and spatial resolution, and it still may not be sufficient to achieve high diagnostic accuracy in all patients (37,38). A comparison of peripheral

Figure 5

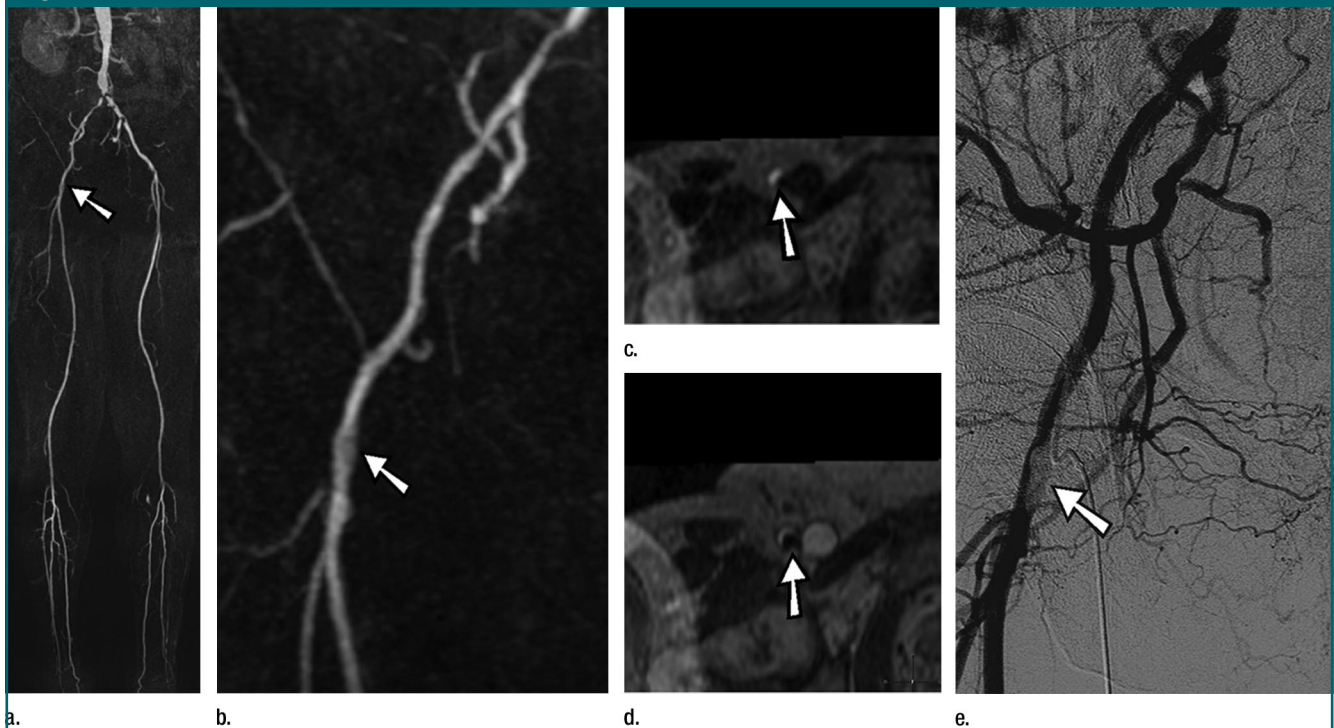


Figure 5: MR angiographic and DSA images of high-grade stenosis of common right femoral artery (arrow) in a 72-year-old man with severe aortoiliac occlusive disease. **(a, b)** Fused maximum intensity projections of moving-table-subtracted contrast-enhanced T1-weighted gradient-echo images (2.7/0.89) during the arterial first pass. **(c)** Cross-sectional multiplanar reformation of contrast-enhanced T1-weighted gradient-echo images (4.8/1.42) during the steady state. **(d)** Cross-sectional multiplanar reformation of high-spatial-resolution contrast-enhanced T1-weighted gradient-echo images (4.8/1.42) during the steady state. **(e)** Anterior view of DSA of right pelvic arteries. Stenosis grading of right common femoral artery (arrow) was judged as less than 50% on first-pass MR angiogram, but 50% or higher on steady-state MR angiogram and DSA image. Note the vast underestimation of stenosis grade on **a** and **b**.

steady-state MR angiography and time-resolved MR angiography may be desirable in the future but was not the aim of the present study. Alternatively, the administration of tourniquets after application of blood pool contrast agent may be advantageous (39).

The diameter of the vessels in the lower legs is particularly small (eg, 2.4 mm for the posterior tibial artery) (40). Hoogeveen et al (41) have shown that at least 3 pixels are needed within the vascular lumen to assess the degree of stenosis with an error of less than 10%. Thus, to correctly judge the grade of stenosis in vessels as small as these, a submillimetric data set is highly desirable. Our results show that the agreement of stenosis grading at MR angiography and DSA is clearly improved with steady-state MR angiography. In renal arteries, it has been shown that lower spatial resolution may lead to both over- and underestimation of the degree of stenosis (26). We observed a similar trend of both over- and underestimation in the stenosis grading of peripheral arteries. Nevertheless, it may be advantageous to further increase spatial resolution and acquisition time of first-pass and steady-state MR angiography with the help of parallel imaging (35). In addition, increased signal-to-noise ratio can be achieved by the application of large coil arrays and acquisition at higher field strengths (eg, 3.0 T), which in return may contribute to the use of high parallel-imaging acceleration factors that allow for further increase of spatial resolution and/or decrease of imaging time. Nikolaou et al (35) have recently shown that by the use of large coil arrays, spatial resolution of $0.5 \times 0.5 \times 0.5$ mm can be achieved in all stations at peripheral MR angiography.

Our study had several limitations. First, the number of patients was limited, and future studies with larger study populations will be needed to increase statistical power. Second, the reading of steady-state MR angiograms was conducted in consensus by two radiologists because we wanted to conduct an intermodality comparison rather than an interobserver comparison. This may be beneficial in follow-up

Table 2
Grade of Stenosis as Evaluated at First-Pass and Steady-State MR Angiography of Arteries of the Lower Extremities

Grade of Stenosis	First-Pass MR Angiography	Steady-State MR Angiography	DSA
0%–49%	242 (72.5)	249 (74.6)	249 (74.6)
50%–99%	43 (12.9)	46 (13.8)	46 (13.8)
100%	49 (14.7)	39 (11.7)	39 (11.7)

Note.—Data are numbers of segments, with percentages in parentheses.

studies. Third, this study demonstrates the higher level of agreement of steady-state MR angiography with DSA but not the clinical effect on patient outcome. One can, however, assume that higher agreement between steady-state MR angiography and DSA may translate in improved selection of candidates for surgery or intervention on the basis of noninvasive steady-state MR angiography alone.

Fourth, while the standard of reference in clinical practice for stenosis grading still is widely accepted to be the measurement of percentage of diameter of stenosis on two-dimensional DSA images, cross-sectional measurement of percentage of area of stenosis has been shown to be more accurate at 3D contrast-enhanced MR angiography than percentage of diameter of stenosis measurement (24,26,27). Nevertheless, we observed 100% agreement of DSA and steady-state MR angiographic readings in spite of the different measurement approaches. Although DSA is usually used as the standard of reference, it is known that DSA has some limitations (eg, evaluation of eccentric stenosis because no axial images are available in biplane DSA).

Finally, both first-pass and steady-state MR angiography were performed with the same injection of a blood pool contrast agent, whereas, as of to date, first-pass MR angiography in clinical practice is usually performed with a gadolinium chelate contrast agent. Prospective data are required that compare first-pass MR angiography with a gadolinium chelate contrast agent with first-pass and steady-state MR angiography with a blood pool contrast agent. However, Klessen et al (33) recently pub-

Table 3
Comparison of First-Pass and Steady-State MR Angiography to DSA according to the Threshold of 50% Stenosis

MR Angiography	DSA		Total
	<50%	≥50%	
First pass			
<50%	227	15	242
≥50%	22	70	92
Steady state			
<50%	249	0	249
≥50%	0	85	85

Data are numbers of segments.

Table 4
Comparison of First-Pass and Steady-State MR Angiography to DSA according to the Threshold of Patency

MR Angiography	DSA		Total
	Patent	Occluded	
First pass			
Patent	285	0	285
Occluded	10	39	49
Steady state			
Patent	295	0	295
Occluded	0	39	39

Data are numbers of segments.

lished results on the comparison of gadofosveset trisodium to a standard gadolinium chelate contrast agent at whole-body first-pass MR angiography and found first-pass MR angiography with a blood pool contrast agent to be of at least as good quality as that of first-pass MR angiography with a gadolinium chelate contrast agent. In addition, sen-

sitivity, specificity, and positive and negative predictive values of first-pass MR angiography with gadofosveset trisodium reported in our study are in the range of those in the literature with a gadolinium chelate contrast agent (30). Despite the limitations, the intraindividual study design with first-pass and steady-state MR angiography within the same session with one injection of a blood pool contrast agent may reduce variability between both examinations. Furthermore, it may be considered an advantage for clinical practice to perform both first-pass and steady-state MR angiography with a single injection of a blood pool contrast agent as it was done in our study design.

In clinical practice, we have therefore started to regard steady-state MR angiography as an add-on that may possibly increase diagnostic accuracy. We start the image interpretation procedure with standard-resolution arterial-only maximum intensity projections of subtracted first-pass MR angiographic data, because we regard the strength of first-pass MR angiographic acquisitions in the selection of nonstenosed arterial segments that do not need further interpretation at steady-state MR angiography. In a second step, we use steady-state MR angiographic acquisitions to specifically review segments of interest on higher resolution images with cross-sectional and manual curved multiplanar reformations following the centerline of the vessel (28). This combination of first-pass and steady-state MR angiographic acquisitions may allow for accelerated yet accurate stenosis grading. This, however, remains to be determined in future studies.

In conclusion, with DSA serving as the standard of reference, high-spatial-resolution steady-state 3D contrast-enhanced MR angiography of the lower extremities with gadofosveset trisodium allowed for increased sensitivity and specificity in the detection of significant stenosis in patients with peripheral arterial occlusive disease compared with standard-resolution arterial-phase first-pass MR angiography with the same contrast agent. It remains to be investigated whether the increase in sensitivity

and specificity that is achieved with steady-state MR angiography will translate into a therapeutic benefit for patients with peripheral arterial occlusive disease.

References

- Hany TF, Debatin JF, Leung DA, Pfammatter T. Evaluation of the aortoiliac and renal arteries: comparison of breath-hold, contrast-enhanced, three-dimensional MR angiography with conventional catheter angiography. *Radiology* 1997; 204:357-362.
- Prince MR, Yucel EK, Kaufman JA, Harrison DC, Geller SC. Dynamic gadolinium-enhanced three-dimensional abdominal MR arteriography. *J Magn Reson Imaging* 1993;3: 877-881.
- Willinek WA, von Falkenhausen M, Born M, et al. Noninvasive detection of stenocclusive disease of the supra-aortic arteries with three-dimensional contrast-enhanced magnetic resonance angiography: a prospective, intra-individual comparative analysis with digital subtraction angiography. *Stroke* 2005;36:38-43.
- Lenhart M, Finkenzeller T, Paetzel C, et al. Contrast-enhanced MR angiography in the routine work-up of the lower extremity arteries [in German]. *Rofo* 2002;174:1289-1295.
- Corot C, Violas X, Robert P, Gagneur G, Port M. Comparison of different types of blood pool agents (P792, MS325, USPIO) in a rabbit MR angiography-like protocol. *Invest Radiol* 2003;38:311-319.
- Huegli RW, Aschwanden M, Bongartz G, et al. Intraarterial MR angiography and DSA in patients with peripheral arterial occlusive disease: prospective comparison. *Radiology* 2006;239:901-908.
- Huston J 3rd, Fain SB, Riederer SJ, Wilman AH, Bernstein MA, Busse RF. Carotid arteries: maximizing arterial to venous contrast in fluoroscopically triggered contrast-enhanced MR angiography with elliptical centric view ordering. *Radiology* 1999;211:265-273.
- Willinek WA, Gieseke J, Conrad R, et al. Randomly segmented central k-space ordering in high-spatial-resolution contrast-enhanced MR angiography of the supraaortic arteries: initial experience. *Radiology* 2002; 225:583-588.
- Leiner T. Magnetic resonance angiography of abdominal and lower extremity vasculature. *Top Magn Reson Imaging* 2005;16: 21-66.
- Schoenberg SO, Lundy FJ, Licato P, Williams DM, Wakefield T, Chenevert TL. Multiphase-multistep gadolinium-enhanced MR angiography of the abdominal aorta and runoff vessels. *Invest Radiol* 2001;36:283-291.
- Goyen M, Edelman M, Perreault P, et al. MR angiography of aortoiliac occlusive disease: a phase III study of the safety and effectiveness of the blood-pool contrast agent MS-325. *Radiology* 2005;236:825-833.
- Rapp JH, Wolff SD, Quinn SF, et al. Aortoiliac occlusive disease in patients with known or suspected peripheral vascular disease: safety and efficacy of gadofosveset-enhanced MR angiography—multicenter comparative phase III study. *Radiology* 2005;236:71-78.
- Goyen M, Shamsi K, Schoenberg SO. Vasovist-enhanced MR angiography. *Eur Radiol* 2006;16(suppl 2):B9-B14.
- Grist TM, Korosec FR, Peters DC, et al. Steady-state and dynamic MR angiography with MS-325: initial experience in humans. *Radiology* 1998;207:539-544.
- Rohrer M, Bauer H, Mintorovitch J, Requardt M, Weimann HJ. Comparison of magnetic properties of MRI contrast media solutions at different magnetic field strengths. *Invest Radiol* 2005;40:715-724.
- Norgren L, Hiatt WR, Dormandy JA, et al. Inter-Society Consensus for the Management of Peripheral Arterial Disease (TASC II). *Eur J Vasc Endovasc Surg* 2007;33(suppl 1):S1-S75.
- Wilman AH, Riederer SJ, King BF, Debbins JP, Rossman PJ, Ehman RL. Fluoroscopically triggered contrast-enhanced three-dimensional MR angiography with elliptical centric view order: application to the renal arteries. *Radiology* 1997;205:137-146.
- Lauffer RB, Parmelee DJ, Dunham SU, et al. MS-325: albumin-targeted contrast agent for MR angiography. *Radiology* 1998;207:529-538.
- Parmelee DJ, Walovitch RC, Ouellet HS, Lauffer RB. Preclinical evaluation of the pharmacokinetics, biodistribution, and elimination of MS-325, a blood pool agent for magnetic resonance imaging. *Invest Radiol* 1997;32:741-747.
- Koelemay MJ, Lijmer JG, Stoker J, Legemate DA, Bossuyt PM. Magnetic resonance angiography for the evaluation of lower extremity arterial disease: a meta-analysis. *JAMA* 2001;285: 1338-1345.
- Hartmann M, Wiethoff AJ, Hentrich HR, Rohrer M. Initial imaging recommendations for Vasovist angiography. *Eur Radiol* 2006; 16(suppl 2):B15-B23.
- Perreault P, Edelman MA, Baum RA, et al.

- MR angiography with gadofosveset trisodium for peripheral vascular disease: phase II trial. *Radiology* 2003;229:811–820.
23. Ota H, Takase K, Rikimaru H, et al. Quantitative vascular measurements in arterial occlusive disease. *RadioGraphics* 2005;25:1141–1158.
 24. Morasch MD, Gurjala AN, Washington E, et al. Cross-sectional magnetic resonance angiography is accurate in predicting degree of carotid stenosis. *Ann Vasc Surg* 2002;16:266–272.
 25. Ruehm SG, Hany TF, Pfammatter T, Schneider E, Ladd M, Debatin JF. Pelvic and lower extremity arterial imaging: diagnostic performance of three-dimensional contrast-enhanced MR angiography. *AJR Am J Roentgenol* 2000;174:1127–1135.
 26. Schoenberg SO, Rieger J, Weber CH, et al. High-spatial-resolution MR angiography of renal arteries with integrated parallel acquisitions: comparison with digital subtraction angiography and US. *Radiology* 2005;235:687–698.
 27. De Marco JK, Nesbit GM, Wesbey GE, Richardson D. Prospective evaluation of extracranial carotid stenosis: MR angiography with maximum-intensity projections and multiplanar reformation compared with conventional angiography. *AJR Am J Roentgenol* 1994;163:1205–1212.
 28. Raman R, Napel S, Beaulieu CF, Bain ES, Jeffrey RB Jr, Rubin GD. Automated generation of curved planar reformations from volume data: method and evaluation. *Radiology* 2002;223:275–280.
 29. Henness S, Keating GM. Gadofosveset. *Drugs* 2006;66:851–857.
 30. Meaney JF, Ridgway JP, Chakraverty S, et al. Stepping-table gadolinium-enhanced digital subtraction MR angiography of the aorta and lower extremity arteries: preliminary experience. *Radiology* 1999;211:59–67.
 31. Fleiss JL. *Statistical methods for rates and proportions*. 2nd ed. New York, NY: Wiley, 1981.
 32. Ruehm SG, Goyen M, Debatin JF. MR angiography: first choice for diagnosis of the arterial vascular system [in German]. *Rofo* 2002;174:551–561.
 33. Klessen C, Hein PA, Huppertz A, et al. First-pass whole-body magnetic resonance angiography (MRA) using the blood-pool contrast medium gadofosveset trisodium: comparison to gadopentetate dimeglumine. *Invest Radiol* 2007;42:659–664.
 34. Bluemke DA, Stillman AE, Bis KG, et al. Carotid MR angiography: phase II study of safety and efficacy for MS-325. *Radiology* 2001;219:114–122.
 35. Nikolaou K, Kramer H, Grosse C, et al. High-spatial-resolution multistation MR angiography with parallel imaging and blood pool contrast agent: initial experience. *Radiology* 2006;241:861–872.
 36. Andreisek G, Pfammatter T, Goepfert K, et al. Peripheral arteries in diabetic patients: standard bolus-chase and time-resolved MR angiography. *Radiology* 2007;242:610–620.
 37. Sharafuddin MJ, Stolpen AH, Sun S, et al. High-resolution multiphase contrast-enhanced three-dimensional MR angiography compared with two-dimensional time-of-flight MR angiography for the identification of pedal vessels. *J Vasc Interv Radiol* 2002;13:695–702.
 38. Zhang HL, Kent KC, Bush HL, et al. Soft tissue enhancement on time-resolved peripheral magnetic resonance angiography. *J Magn Reson Imaging* 2004;19:590–597.
 39. Herborn CU, Ajaj W, Goyen M, Massing S, Ruehm SG, Debatin JF. Peripheral vasculature: whole-body MR angiography with midfemoral venous compression—initial experience. *Radiology* 2004;230:872–878.
 40. Sabatier MJ, Stoner L, Reifenberger M, McCully K. Doppler ultrasound assessment of posterior tibial artery size in humans. *J Clin Ultrasound* 2006;34:223–230.
 41. Hoogeveen RM, Bakker CJ, Viergever MA. Limits to the accuracy of vessel diameter measurement in MR angiography. *J Magn Reson Imaging* 1998;8:1228–1235.